

Atypical infra-renal aortic dissection

Luís Machado^{1,2*} and Armando Mansilha^{1,2}

¹Department of Angiology and Vascular Surgery, São João Hospital Center, Porto e Regiao, Portugal

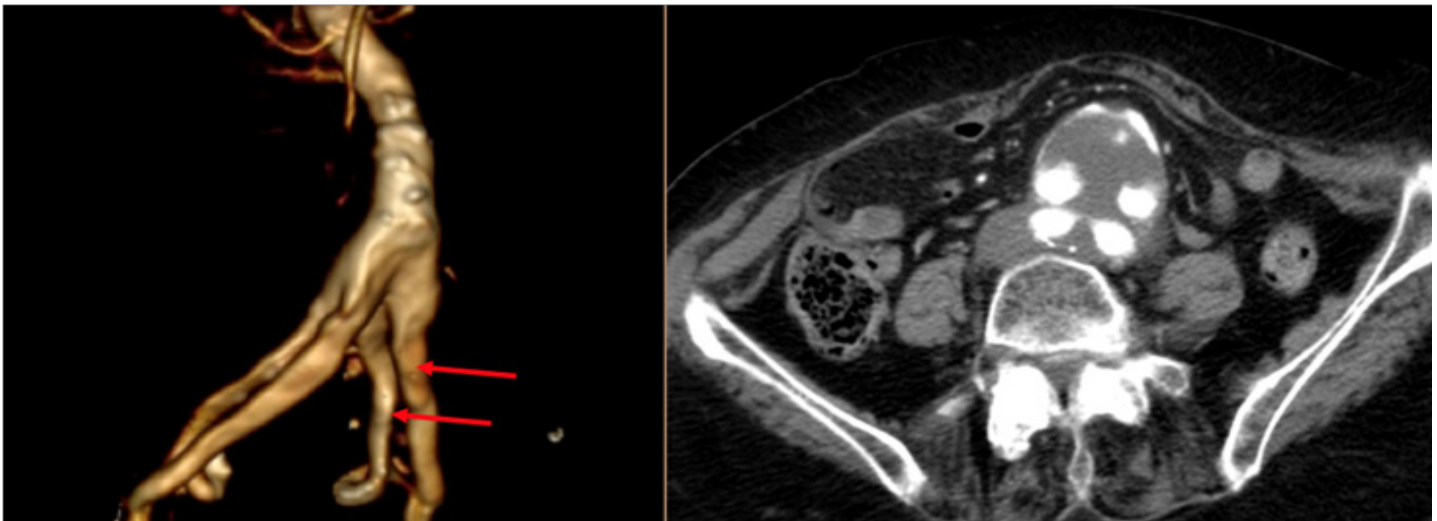
²Faculty of Medicine, Porto University, Praça de Gomes Teixeira, 4099-002 Porto, Portugal

Clinical image

A 93-year-old female patient with previously known infra-renal aortic aneurysm, was admitted due to back pain. Computed tomography angiography revealed an infra-renal aortic dissection, with a curious morphology, since two lumens were visible - one for both the external arteries and another to both hypogastric arteries. There were no signs of impending rupture.

Isolated abdominal aortic dissection is a rare entity and represents 1.3% of all dissections. There are a few case series reported in the literature.

Most patients are asymptomatic and symptoms are usually abdominal or back pain. A pre-existing abdominal aortic aneurysm is present in 42% of cases.



***Correspondence:** Luís Machado, Department of Angiology and Vascular Surgery, São João Hospital Center, Porto e Regiao, Portugal; E-mail: lmachado.med@gmail.com

Rec: Nov 06, 2018; Acc: Nov 20, 2018; Pub:Nov 23, 2018

J Clin Med Imag. 2018;1(2):9
DOI: gsl.jcimi.2018.00009

Copyright © 2018 The Author(s). This is an open-access article distributed under the terms of the Creative Commons Attribution 4.0 International License (CC-BY).